International Journal of Medicine
pISSN 1468-3814 | eISSN 2667-7008
https://theinternationalmedicine.com/

Case Series *DOI: 10.61336/im/26-11-59*

Intra-operative and Pre-operative Rupture in Wilms Tumor Management: An 8-Year Institutional Case Series.

Dr. Vinay Kumar M N[1*], Dr. Vinay Jadhav[2], Dr. Varun G Huilgol[3]

[1]*Associate Consultant, Department of Paediatric Surgery, Sakra World Hospital, Bangalore, India.*

[2]*Associate Professor, Department of Paediatric Surgery, Indira Gandhi Institute of Child Health, Bangalore, India.*

[3]*Uro-Oncology and Robotic Surgery Fellow, Department of Uro-Oncology, HCG Astha Cancer Centre, Ahmedabad, India*

Correspondence:
Dr Vinay Kumar M N.
Associate Consultant, Department of Paediatric Surgery, Sakra World Hospital, Bangalore, India.

Email:
vinaykumarmn95@gmail.com

Received: 12-08-2026
Revised: 10-09-2026
Accepted: 14-10-2026
Published: 25-11-2026

Abstract

Background: Tumor rupture in Wilms tumor (WT) upstages disease and intensifies therapy. We describe six children with ruptured WT among 52 treated at a tertiary paediatric centre in India between 2014 and 2022 (11.5%): two pre-operative and four intra-operative ruptures. Three intra-operative ruptures occurred after neoadjuvant chemotherapy (NACT), one after six cycles. All received protocol-based adjuvant chemotherapy and whole-abdomen radiotherapy. One child with metastatic disease died, one had a tumor-bed recurrence that was salvaged, and four remained event-free for 27–72 months. NACT does not abolish rupture risk; meticulous surgery and strict adherence to adjuvant therapy remain essential.

Keywords: Wilms tumor, tumor rupture, neoadjuvant chemotherapy, paediatric oncology, surgical spillage, local recurrence.

This article is an open access article distributed under the terms and conditions of the Creative Commons Attribution (CC-BY) license (http://creativecommons.org/licenses/by/4.0/).

INTRODUCTION

Wilms tumor (WT) is the commonest renal malignancy of childhood, and survival now exceeds 85–90% with multimodal therapy.1,2 Tumor rupture, a macroscopic breach of the tumor capsule with spillage of tumor cells, remains an adverse event within this favourable landscape. It may occur before surgery, spontaneously or after trauma, or during resection. Either way, disease is upstaged to at least stage III, mandating whole-abdomen radiotherapy and intensified chemotherapy, and the risk of local relapse rises.3–5 The two dominant strategies differ in this respect: the Children's Oncology Group favours upfront nephrectomy, whereas SIOP protocols give preoperative chemotherapy, so spill carries different staging and treatment implications in each.2 Preoperative chemotherapy shrinks tumors and is expected to lower rupture risk, yet whether it prevents rupture in bulky tumors remains uncertain.2,6 In low- and middle-income settings, late presentation and bulky tumors compound the problem.7 Indian series describe late presentation, large tumors and suboptimal survival,8 but case-level reporting of rupture is limited. We describe six children with pre-operative or intra-operative rupture managed at our institution over eight years, emphasising the circumstances, treatment and outcome of each.

CASE PRESENTATION

Six children with ruptured WT, five girls and one boy with a median age of 4 years (one under 1 year, three aged 1–5 years, two over 5 years), represented 11.5% of 52 children treated at our centre. Rupture was pre-operative in two (3.8%) and intra-operative in four (7.7%). All tumors were unilateral and one child had lung metastases. Details are summarised in Table 1.

Pre-operative rupture

CASE 1

A child presented late with a large right renal mass (10 × 13 × 7 cm) showing clinical and radiological evidence of rupture, with pulmonary metastases. Treatment was delayed; one cycle of NACT was given, but rupture with clinical deterioration necessitated emergency right nephrectomy. Histology showed blastemal-predominant WT, stage IV, intermediate risk.

Adjuvant etoposide, carboplatin, cyclophosphamide and doxorubicin were given with whole-abdomen and pulmonary radiotherapy. Although no local recurrence was documented, the child succumbed to disease at 15 months.

CASE 2

A child presented with a right renal tumor (recorded as 11 × 8 × 8 × 10.1 cm) with clinical and radiological features of rupture and no metastasis. Without NACT, upfront right nephrectomy was performed. Histology was triphasic WT, stage III, intermediate risk. Vincristine, actinomycin-D and doxorubicin were given with whole-abdomen radiotherapy. The child remained event-free at 72 months.

Intra-operative rupture

CASE 3

A child with a localised 11.5 × 9.7 × 9.6 cm tumor and no pre-operative signs of rupture underwent upfront nephroureterectomy with lymph-node sampling. Intra-operative rupture (Figure 1) upstaged the disease to stage III. Histology showed focal anaplasia. Vincristine, actinomycin-D and doxorubicin were given with whole-abdomen radiotherapy. A tumor-bed recurrence at 24 months was salvaged with etoposide, cyclophosphamide, carboplatin and radiotherapy.

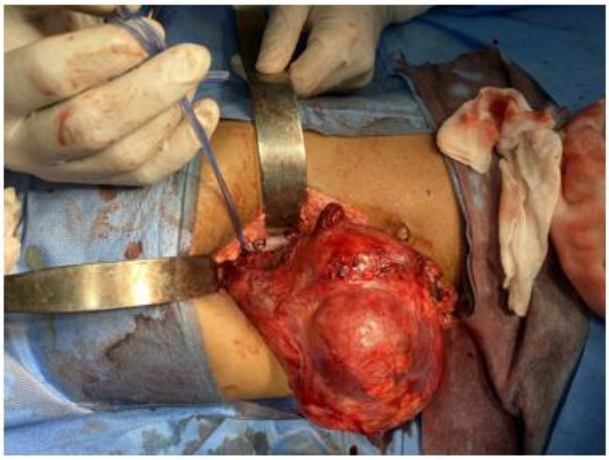

Figure 1: Operative image showing right-sided Wilms tumor with intra-operative rupture and tumor spillage.

CASE 4

A child with a 14 × 11 × 19 cm localised tumor and no pre-operative rupture received six cycles of NACT, yet rupture occurred during nephroureterectomy with lymph-node sampling. Histology was triphasic, stage III, intermediate risk. Adjuvant vincristine, actinomycin-D, doxorubicin and whole-abdomen radiotherapy followed; the child was event-free at 27 months.

CASE 5

A child with a 15 × 8 × 11 cm localised tumor received two cycles of NACT; rupture occurred at nephroureterectomy with lymph-node sampling, probably influenced by bulk and incomplete chemotherapy. Histology was triphasic, stage III, intermediate risk. Standard adjuvant chemotherapy and whole-abdomen radiotherapy were given; the child was event-free at 48 months.

CASE 6

A child with localised WT received one cycle of NACT before nephroureterectomy with lymph-node sampling, complicated by intra-operative rupture. Tumor dimensions were not available in the retrievable record. Histology was triphasic, stage III, intermediate risk. Adjuvant vincristine, actinomycin-D, doxorubicin and whole-abdomen radiotherapy were given; the child was event-free at 36 months.

Table 1: Summary of clinical, operative and histopathological characteristics

Variable	Case 1	Case 2	Case 3	Case 4	Case 5	Case 6
Rupture	Pre-op	Pre-op	Intra-op	Intra-op	Intra-op	Intra-op
Presentation	Metastatic	Localised	Localised	Localised	Localised	Localised
Tumor size (cm)	10×13×7	11×8×8×10.1	11.5×9.7×9.6	14×11×19	15×8×11	N/A

NACT (cycles)	1	None	None	6	2	1
Pre-op rupture signs	Yes	Yes	No	No	No	No
Surgery	Emergency R nephrectomy	R nephrectomy	Nephro-ureterectomy + LN sampling	Same	Same	Same
Histology	Blastemal	Triphasic	Focal anaplasia	Triphasic	Triphasic	Triphasic
Stage / risk	IV / IR	III / IR	III / IR	III / IR	III / IR	III / IR
Adjuvant chemo	ETO/CARBO/CYC/DOX	VCR/ACT-D/DOX	VCR/ACT-D/DOX	VCR/ACT-D/DOX	Standard	VCR/ACT-D/DOX
Radiotherapy	Abdomen + lung	Whole abdomen	Whole abdomen	Whole abdomen	Whole abdomen	Whole abdomen
Follow-up (months)	15	72	24	27	48	36
Recurrence	No	No	Yes (tumor bed)	No	No	No
Outcome	Died	Event-free	Salvaged	Event-free	Event-free	Event-free

NACT, neoadjuvant chemotherapy; IR, intermediate risk; N/A, not available; ETO, etoposide; CARBO, carboplatin; CYC, cyclophosphamide; DOX, doxorubicin; VCR, vincristine; ACT-D, actinomycin-D; LN, lymph node.

DISCUSSION

Rupture occurred in 11.5% of our children with WT (pre-operative 3.8%, intra-operative 7.7%). Every case was upstaged to stage III or above and treated accordingly; five of six children are alive and four are event-free at 27–72 months. This supports the view that spillage escalates therapy without necessarily precluding cure.3–6

In Children's Oncology Group experience, where upfront nephrectomy is standard, intra-operative spill occurred in 15.5–26.1% of nephrectomies, depending on whether adrenalectomy was performed.9 In SIOP 93-01/GPOH, intra-operative rupture occurred in 12% of primarily operated patients versus 3.2% after preoperative chemotherapy.10 A central Indian series likewise found significantly less tumor spill after preoperative chemotherapy.8 Our intra-operative rate (7.7%) lies between these figures, although we lack denominators by NACT status for formal comparison. The two pre-operative ruptures are in keeping with the late presentation, bulky tumors and treatment delay described in low-resource settings;7,8 case 1 illustrates this combination. Case 2 underwent upfront nephrectomy after pre-operative rupture and, with stage III chemotherapy and whole-abdomen radiotherapy, remained event-free at 72 months, the longest follow-up in our series, showing that early surgery with protocol-based therapy can cure.3,5

Three intra-operative ruptures followed NACT (one, two and six cycles). In SIOP 93-01, preoperative chemotherapy achieved 5-year event-free survival of 90% in stage II–III intermediate-risk tumors, yet larger tumor volume at surgery and blastemal histology predicted worse outcome.6 Consistently, the child who completed six cycles (case 4) still had a 14 × 11 × 19 cm mass, and case 5 had a 15 cm tumor after two cycles. Bulk and technical difficulty, rather than the number of cycles alone, may determine fragility. NACT reduces but cannot remove the risk,2,6 and in SIOP 93-01/GPOH midline laparotomy and low surgeon volume were also linked to more ruptures.10 Careful exposure, avoidance of traction and meticulous handling therefore remain mandatory.11

Triphasic histology was present in three of four intra-operative ruptures. Because WT classically comprises blastemal, epithelial and stromal elements,12 triphasic histology is common, and this probably reflects prevalence rather than intrinsic capsular fragility. Chemotherapy-induced necrosis or fibrosis could alter tumor consistency, but our numbers cannot test this; post-chemotherapy histological subtype defines risk group and prognosis,12 yet rupture-specific data are lacking.

The prognostic weight of spillage is well documented. In NWTS-4, spill increased local relapse risk, whether localised or diffuse, and lymph-node sampling proved important;3 all four of our intra-operative cases had nodes sampled. Among stage II favorable-histology patients, 8-year relapse-free survival was 75.7% with spill versus 85.0% without.4 Abdominal recurrence after spillage also depends on the intensity of chemotherapy and radiotherapy.5 In SIOP WT 2001, high-risk histology, age of 2 years or more and preoperative tumor volume were independent risk factors for local relapse.13 Our single tumor-bed recurrence (1/6, 16.7%) occurred at 24 months in a child with a large tumor and focal anaplasia, which may have contributed. Stage III therapy with whole-abdomen radiotherapy, as applied here, follows the escalation these

data imply, and salvage succeeded. Structured imaging surveillance is essential because early detection of relapse underpins salvage.14 SIOP WT 2001 showed that doxorubicin could be omitted from stage II–III intermediate-risk treatment after NACT (blastemal-type tumors excluded) without loss of efficacy;15 whether this holds for ruptured tumors remains uncertain.

Two practical measures follow. First, early referral and prompt initiation of NACT may prevent pre-operative rupture where presentation is late.7,8 Second, tumors that remain bulky after NACT warrant an experienced surgeon, a transverse or thoracoabdominal incision and planned lymph-node sampling.10,11

The only death (case 1) combined stage IV disease, blastemal-predominant histology, delayed treatment and pre-operative rupture. Because blastemal histology and advanced stage are recognised adverse factors,6 rupture was probably one of several contributors. Limitations include small numbers, retrospective design, missing tumor size in case 6, and absence of baseline data for the 46 children without rupture, which precludes formal risk-factor analysis.

CONCLUSION

Tumor rupture in WT, whether pre-operative or intra-operative, mandates stage-appropriate multimodal therapy and structured surveillance, and good outcomes remain achievable. In this series, NACT, even six cycles, did not eliminate intra-operative rupture, particularly in bulky tumors. Early referral, timely NACT, meticulous surgical technique with lymph-node sampling, and strict adherence to adjuvant chemotherapy and radiotherapy are the key measures to limit spillage and its consequences.

REFERENCES

1. Spreafico F, Fernandez CV, Brok J, Nakata K, Vujanic G, Geller JI, et al. Wilms tumour. Nat Rev Dis Primers. 2021;7(1):75.
2. Dome JS, Graf N, Geller JI, Fernandez CV, Mullen EA, Spreafico F, et al. Advances in Wilms tumor treatment and biology: progress through international collaboration. J Clin Oncol. 2015;33(27):2999-3007.
3. Shamberger RC, Guthrie KA, Ritchey ML, Haase GM, Takashima J, Beckwith JB, et al. Surgery-related factors and local recurrence of Wilms tumor in National Wilms Tumor Study 4. Ann Surg. 1999;229(2):292-7.
4. Green DM, Breslow NE, D'Angio GJ, Malogolowkin MH, Ritchey ML, Evans AE, et al. Outcome of patients with stage II/favorable histology Wilms tumor with and without local tumor spill: a report from the National Wilms Tumor Study Group. Pediatr Blood Cancer. 2014;61(1):134-9.
5. Kalapurakal JA, Li SM, Breslow NE, Beckwith JB, Ritchey ML, Shamberger RC, et al. Intraoperative spillage of favorable histology Wilms tumor cells: influence of irradiation and chemotherapy regimens on abdominal recurrence. A report from the National Wilms Tumor Study Group. Int J Radiat Oncol Biol Phys. 2010;76(1):201-6.
6. Graf N, van Tinteren H, Bergeron C, Pein F, van den Heuvel-Eibrink MM, Sandstedt B, et al. Characteristics and outcome of stage II and III non-anaplastic Wilms' tumour treated according to the SIOP trial and study 93-01. Eur J Cancer. 2012;48(17):3240-8.
7. Israels T, Moreira C, Scanlan T, Molyneux L, Kampondeni S, Hesseling P, et al. SIOP PODC: clinical guidelines for the management of children with Wilms tumour in a low income setting. Pediatr Blood Cancer. 2013;60(1):5-11.
8. Agrawal V, Mishra A, Yadav SK, Sharma D, Acharya H, Mishra A, et al. A 10-year study of the outcome of Wilms' tumor in central India and identifying practice gaps. J Indian Assoc Pediatr Surg. 2022;27(1):42-52.
9. Kieran K, Anderson JR, Dome JS, Ehrlich PF, Ritchey ML, Shamberger RC, et al. Is adrenalectomy necessary during unilateral nephrectomy for Wilms tumor? A report from the Children's Oncology Group. J Pediatr Surg. 2013;48(7):1598-603.
10. Fuchs J, Kienecker K, Furtwängler R, Warmann SW, Bürger D, Thüroff JW, et al. Surgical aspects in the treatment of patients with unilateral Wilms tumor: a report from the SIOP 93-01/German Society of Pediatric Oncology and Hematology. Ann Surg. 2009;249(4):666-71.
11. Kieran K, Ehrlich PF. Current surgical standards of care in Wilms tumor. Urol Oncol. 2016;34(1):13-23.
12. Vujanić GM, Gessler M, Ooms AHAG, Collini P, Coulomb-l'Hermine A, D'Hooghe E, et al. The UMBRELLA SIOP-RTSG 2016 Wilms tumour pathology and molecular biology protocol. Nat Rev Urol. 2018;15(11):693-701.
13. Irtan S, van Tinteren H, Graf N, van den Heuvel-Eibrink MM, Heij H, Bergeron C, et al. Evaluation of needle biopsy as a potential risk factor for local recurrence of Wilms tumour in the SIOP WT 2001 trial. Eur J Cancer. 2019;116:13-20.
14. Brok J, Lopez-Yurda M, van Tinteren H, Treger TD, Furtwängler R, Graf N, et al. Relapse of Wilms' tumour and detection methods: a retrospective analysis of the 2001 Renal Tumour Study Group-International Society of Paediatric Oncology Wilms' tumour protocol database. Lancet Oncol. 2018;19(8):1072-81.
15. Pritchard-Jones K, Bergeron C, de Camargo B, van den Heuvel-Eibrink MM, Acha T, Godzinski J, et al. Omission of doxorubicin from the treatment of stage II-III, intermediate-risk Wilms' tumour (SIOP WT 2001): an open-label, non-inferiority, randomised controlled trial. Lancet. 2015;386(9999):1156-64.